

Limping Child Pathway

Clinical Assessment/ Management tool for Children



Management - Primary Care and Community Settings

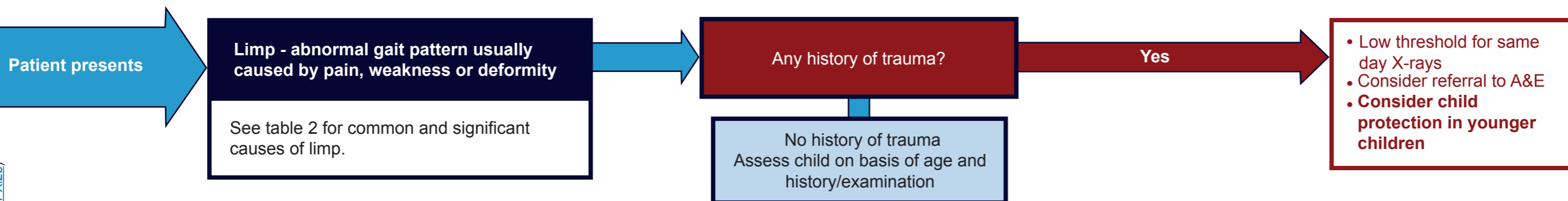


Table 1

Green	Amber	Infection (SA/OM) red Flags	Malignancy red flags
Symptoms less than 72 hours or >72 hours and improving	Symptoms more than 72 hours and no improvement	Temperature >38.5°C in preceding week	Fatigue, anorexia, weight loss, night sweats
Mobile but limping	No red flags	Unable to weight bear	Pain waking child at night
Well		Pain on moving joint (passive)	
No red flags			

Green Action: Likely Transient Synovitis

- Provide with age appropriate **advice sheet**
- Regular analgesia with ibuprofen and paracetamol
- If any safeguarding concerns or concerns about slipped upper femoral epiphysis, low threshold for same day Xrays.
- Review in 48 - 72 hours

Amber Action

- Phone secondary care as per local pathway to arrange **urgent assessment**

Urgent Action

- Phone secondary care as per local pathway to arrange **urgent assessment**

Urgent Action

- Phone Paediatrician-On-Call to arrange **urgent assessment**

If not improving at 48-72 hours, not resolved by 1 week or any uncertainty about diagnosis

GMC Best Practice recommends: Record your findings (See "Good Medical Practice" <http://bit.ly/1DPX12b>)

First Draft Version: November 2017 Review Date: November 2019.

Limping Child Pathway

Clinical Assessment/ Management tool for Children



Management - Primary Care and Community Settings

Table 2: Causes of limp by age

Age Less than 3 Years	Age 3 – 10 years	Older than 10 years	Any Age
<p>Septic arthritis (SA)/ osteomyelitis (OM)</p> <ul style="list-style-type: none"> • Usually febrile. • Most commonly occurs under 4 years of age. • Pain + inability to bear weight. • If SA hip, hip often held flexed and abducted. • Child often looks unwell and passive movement of the joint extremely painful. <p>• Septic arthritis is a medical emergency requiring urgent treatment.</p> <ul style="list-style-type: none"> • Femoral osteomyelitis presents similarly to septic arthritis with fever and pain but children have some passive range of motion unless there is extension of the infection into the joint. <p>Transient synovitis is less common below 3 years of age.</p> <p>Fracture/ soft tissue injury</p> <p>Developmental dysplasia of hip</p> <p>Toddler fracture</p> <p>Non Accidental Injury</p>	<p>Transient synovitis</p> <ul style="list-style-type: none"> • Typically acute onset following a viral infection. • No systemic upset. • Peak onset age 5/6 years, more common in boys. • Managed with oral analgesia. • No pain at rest and passive movements are only painful at the extreme range of movement. • Recurs in up to 15% of children. <p>Septic arthritis (SA)/ osteomyelitis (OM)</p> <p>Fracture/soft tissue injury</p> <p>Perthes disease</p> <ul style="list-style-type: none"> • Usually occurs in children aged 4-10 years (peak 5 and 7 years.) • Affects boys more than girls • Bilateral in 10% 	<p>Septic arthritis (SA) / osteomyelitis (OM)</p> <p>Slipped upper femoral epiphysis</p> <ul style="list-style-type: none"> • Usually occurs aged 11-14 years. • More common in obese children and in boys. • Bilateral in 20-40%. • May present as knee pain • Same day Xray essential – delayed treatment associated with poor outcome. <p>Perthes disease</p> <p>Fracture/soft tissue injury</p>	<p>Septic arthritis (SA) / osteomyelitis (OM)</p> <p>Malignancy including leukaemia</p> <p>Non-malignant haematological disease e.g. haemophilia, sickle cell</p> <p>Metabolic disease e.g. rickets</p> <p>Neuromuscular disease e.g. cerebral palsy, spina bifida</p> <p>Limb abnormality e.g. length discrepancy</p> <p>Inflammatory joint or muscle disease e.g. JIA</p> <ul style="list-style-type: none"> • Affects the hips in 30-50% of cases and is usually bilateral. • Uncommon for hip monoarthritis to be the initial manifestation. • Children typically present with groin pain but may have referred thigh or knee pain. Often have morning stiffness, with gradual resolution of pain with activity. • There is painful or decreased range of motion, especially in internal rotation.